

## HYPOTONIC MR DUODENOGRAPHY IN EVALUATION OF PERYAMPULLARY DUODENAL DIVERTICULA

Plamen Getsov<sup>1</sup>, Borislav Vladimirov<sup>2</sup>

<sup>1</sup>Department of Diagnosting Imaging, Queen Joanna Hospital, 8 Bialo more St, Sofia1527, Bulgaria,  
getsov@isul.eu

<sup>2</sup>Department of Gastroenterology, Queen Joanna Hospital, 8 Bialo more St, Sofia1527, Bulgaria

### Abstract

Diverticulosis of the gastrointestinal tract is considered a disease of the modern world. This fact is explained by reduced fiber content of food in daily diet and aging. 80% of primary duodenal diverticula arising in retroperitoneal space medial to the second part of the duodenum at a distance of 20 mm from the ampulla of Vater. This group is known as periampullary diverticula (PAD). Proper display of the duodenal lumen and disease processes in its wall depends on its optimal distension and relaxation. Modern cross sectional imaging techniques, including computed tomography (CT) and magnetic resonance (MRI) have several shortcomings in the depiction of the duodenum because of its more complex anatomic structure, leading to its suboptimal imaging. To correct these deficiencies it is required use of drugs affecting peristaltic activity of smooth muscle in combination with oral contrast agent and distension of intestinal lumen.

**Keywords:** periampullary diverticula, magnetic resonance, hypotonic duodenography

### 1. Introduction

The duodenum have the second highest incidence of diverticulosis in gastrointestinal tract after the colon. The majority of small bowel diverticula are located in duodenum. 90% of duodenal diverticula are single. The reason for the high incidence of PAD is the presence of congenital weakness of the duodenal wall in the area where the common bile duct and the pancreatic duct enter the lumen of the intestine. Moreover, the penetration of blood vessels in the mucous membrane, lead to further weakness in the wall and potentiates the formation of diverticula.

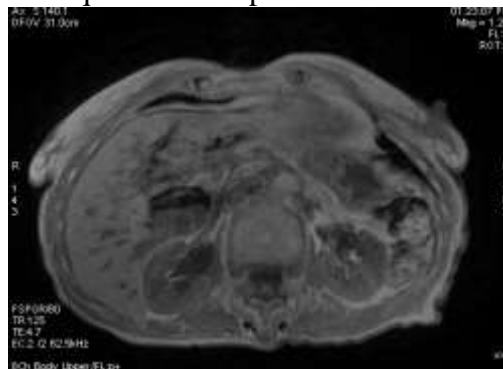
MRCP in combination with hypotonic duodenography with water ingestion alone as a contrast agent is reliable and relatively quick method for testing of patients with biliary and pancreatic pathology in combination with duodenal diverticula. The type and volume of oral contrast agent used have great importance. It is also essential the time elapsed since the water intake and the start of the acquisition and the duration of the study. [1,2].

### 2. Presentation of case

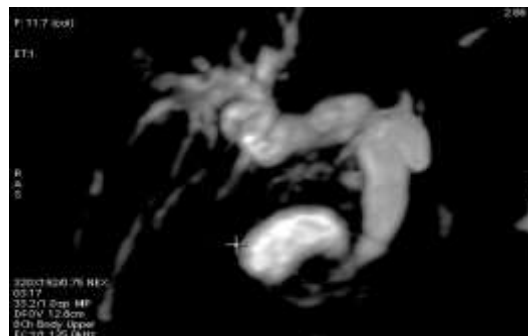
77 years old Caucasian woman is hospitalized in Department of Gastroenterology with chronic pain in the right upper quadrant of the abdomen and severe weight loss. There is a slight elevation of AST (45 U/L), ALT (65 U/L) and marked increase of ALP (272 U/L) and GGT (303 U/L). The other blood tests are normal. The patient has cholecystectomy 14 years before hospitalization. Previous US and CT examinations finds dilatation of the intrahepatic and extrahepatic bile ducts. CT suspects cystic lesion in the pancreatic head.

MRCP is obtained to evaluate anatomy of biliary tree and pancreatic duct and its relationship with the suspect cystic lesion. The study was carried out on the GE Signa HDx 1.5 T machine with 8ch body upper coil. According to available anamnestic information and specifics of the case before the start of the study patient drink 1000 ml of tape water as a positive intraluminal contrast agent. After completion of the initial acquisition including 3D MRCP ASSET (TR

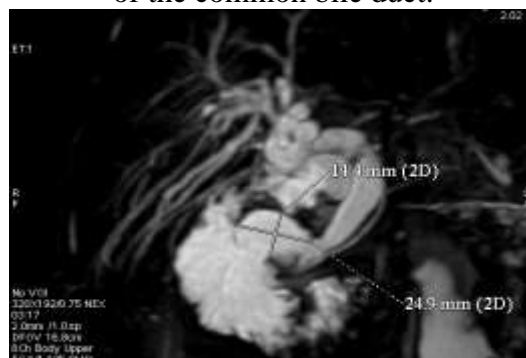
5455ms, TE 785,7ms), T1 Dual Echo (In phase and out of phase TR 125ms TE 2,4/4,7ms) in axial plane and T2 FIESTA in coronary plane (TR 6,8ms, TE 3.0ms), the patient was administered intravenously 20mg hyoscine butylbromide. Then the patient lies one minute to the right lateral position and the acquisition is repeated.



**Fig. 1** T1 Dual Echo out of phase image demonstrates lesion with air-fluid level in the pancreatic head region.



**Fig. 2** 3D MRCP image demonstrates liquid lesion along the distal part of the common bile duct. There is also dilatation of the biliary tree and conical deformation of preampullary region of the common bile duct.



**Fig. 3** 3D MRCP image, after hyoscine butylbromide administration. The duodenal lumen is well extended and the diverticular neck can be seen. Confluence of the common bile and pancreatic duct to the duodenal lumen, and their relation to PAD is easily visible

Patient is undergoing ERCP which confirms the presence of PAD and stenosing papillitis. It is performed endoscopic papilotomy. After the manipulation there is observed relief of complaints of the patient and normalization of liver enzymes.

### 3. Discussion

Duodenal diverticulum is described for the first time by Chomel in 1710. The first well-documented scientific report on this subject is made by Morgagni in 1762. At that time they are considered as anatomic abnormality. Rosental in 1908 reports 3 cases of periampullary

diverticula in combination with biliary obstruction. The first radiological demonstration is realized in 1913 from Case. Since then, numerous studies have been carried out involving different number of patient groups, studying the incidence, diagnostic methods and the relationship between PAD and diseases of the biliary system. In the 60's and 70's of last century the primary method for diagnosis of PAD is hypotonic duodenography. Cross sectional techniques currently used have many shortcomings in the depiction of the duodenum. Most authors use as contrast agent polyethylene glycol in a quantity of 600 to 1000 ml in the MRI examinations of the small intestine. Some authors recommend filling of intestinal lumen with liquid to be combined with intravenous application of hyoscine butylbromide in order to reduce peristaltic activity and to improve distension of small bowel. Currently, several messages appear on the successful use of water as a contrast agent in these cases [1, 9].

PAD are rarely discussed problem during MRI and publications on this subject are few [1, 2, 6, 8]. Duodenal diverticula can be easily identified during the MRT, when (like CT) are filled with gas or a combination of gas and liquid. MRI demonstrates cystic formation with different diameter, which is positioned adjacent to the common bile duct and pancreas. Heavily T2 weighted sequences as true FISP (Fast Imaging with Steady state Precession) HASTE (Half Fournier single Shot Fast Spin Echo) are able to demonstrate and liquid levels in diverticulum. If the contents of the PAD is completely liquid there may be errors in the interpretation of the image, particularly the cystic tumor of the pancreas. The differential diagnosis of cystic lesions in the region of the head of the pancreas include cystic neoplastic lesion, pancreatic pseudocyst and PAD. In such situations, careful analysis of the images is crucial. The establishment of small quantities of gas or a combination of liquid and gas determine the diagnosis. When the distinction between PAD and cystic tumor of the pancreas is not possible, most authors recommend further use of oral contrast [2, 4, 5]. For this purpose, most commonly are used superparamagnetic iron oxide orally in a volume of 400 ml [2, 6, 8]. Additional MRI images demonstrate signal cancellation in the lesion due to influx of contrast agent in diverticula. This allows exclusion of cystic neoplasm of the pancreatic head [2, 8].

Mazzioti et al [7] in the targeted study find that the timely oral administration of a negative contrast allows direct and clear imaging of duodenal diverticula. For their group this was valid for all patients. This allows for an immediate diagnosis and remove the need further studies. The authors view limitation of this approach in the fact that in the majority of centers during acquisition of the images is not present physician. Therefore, in most cases, application of an oral contrast become the second stage. In addition, application of negative contrast is able to significantly improve the quality of images due to the interference suppressor present in the intestinal lumen fluid. In conclusion, the authors emphasize that the use of negative oral contrast for better organization of work can and should be done in one stage, which greatly reduces the overall time to study and improve diagnosis.

MRCP images in coronary plan best demonstrate the attitude of the diverticulum to the papilla. MRI images provide more detailed information regarding the complicated duodenal diverticula, while MRCP allow assessment of the impact of PAD on and bile and pancreatic duct. Intraluminal duodenal diverticula are found better with CT and endosonography [2, 3]

Study on the possibilities of the different sequences in the detection of PAD was carried out by Morita et al [9]. The authors compare the capabilities of the 3D segmented FISP MRCP conventional MRCP sequences using negative oral contrast. In the 42 endoscopically verified people (21 with and 21 without PAD) were performed 3 magnetic resonance sequences-3D true FISP MRCP, two-dimensional rapid acquisition with relaxation enhancement 2D RARE-MRCP and 3D TSE MRCP. Acquisition is performed after oral administration of a negative contrast agent. the sensitivity, specificity and accuracy of the identification of PAD in 3D true FISP MRCP (respectively 61.9%, 85.7% and 73.8%) were significantly higher than those

pri2D RARE-MRCP and 3D TSE MRCP (95%, 100%, 54.8%). Correlation between individual researchers pri3D true FISP MRCP is good ( $k = 0,55$ ).

#### 4. Conclusion

MRCP in combination with hypotonic duodenography and use of water as a contrast agent is reliable and relatively fast method for the study of patients with biliary and pancreatic pathology in combination with PAD. The process does not use ionizing radiation and allows the multiplanar reconstruction of the bile duct, pancreatic duct and diverticulum, for assessment of their spatial relationship. The ability of the method to provide both excellent contrast and good spatial resolution make it into a valuable tool in the arsenal of the radiologists, gastroenterologists and surgeons.

#### References

1. Cronin CG, Dowd G, Mhuirheartaigh JN, DeLappe E, Allen RH, Roche C, Murphy J. Hypotonic MR duodenography with water ingestion alone: feasibility and technique. *Eur Radiol* (2009) 19: 1731-1735.
2. Cronin CG, Dowd G, Macari M, Lazrus D, Israel G, Megibow A. Duodenal diverticula mimicking cystic neoplasm of pancreas: CT and MR imaging findings in seven patients. *AJR* 2003; 180: 195-199.
3. Cronin CG, Lohan DG, DeLappe E, Roche C, Murphy JM. Duodenal Abnormalities at MR Small-Bowel Follow-Through. *AJR* (2008)191:1082-1093.
4. Dineva S, Prodanova K, Mlachkova D, Modeling Data for Pancreatitis in Presence of a Duodenal Diverticula using Logistic Regression, Series of American Institute of Physics, 2014, 39-46.
5. Getsov P, Dineva S, Vladimirov B. Endoscopic retrograde cholangiopancreatography in patients with periampullary diverticula: analysis of 3259 cases. *Journal of Medical Sciences and Public Health*, ORIC Publications, 2014, 3 (2), 35-42.
6. Lawrance IC, Welman CJ, Shipman P, Murray K. Small bowel MRI enteroclysis or follow through: Which is optimal?. *World J Gastroenterol* 2009 November 14; 15(42): 5300-5306
7. Mazziotti S, Costa C, Ascenti G, Gaeta M, Pandolfo A, Blandino A. MR Cholangiopancreatography Diagnosis of Juxtapapillary Duodenal Diverticulum Simulating a Cystic Lesion of the Pancreas: Usefulness of an Oral Negative Contrast Agent. *AJR*: (2005)185: 432-434.
8. Minowa O, Yutaka O, Kyogoku S, Shinoh N, Sumi Y, Katayama H. MR Imaging of the Small Bowel Using Water as a Contrast Agent in a Preliminary Study with Healthy Volunteers. *AJR* (1998) 173: 581-583.
9. Morita S, Ueno E, Masukawa A, Suzuzki K, Machida H, Fujimura M. Defining juxtapapillary diverticulum with 3D segmented true FISP MRCP: comparison with conventional MRCP sequences with an oral negative contrast agent. *Japanese Journal of Radiology*. 2009(27):423-429.